

The Airway, Breathing and Orthodontics

Dr. David C. Page & Dr. Derek Mahony

Airway, Breathing and Malocclusion

Abstract

Dentists need to play a bigger role in managing airway development and craniofacial formation even though the relationship between the airway, breathing and malocclusion remains quite controversial. Certainly, the airway, mode of breathing, and craniofacial formation are so inter-related during growth and development that form can follow function and function can follow form. So, it is imperative to normalize form and function as early as possible, so that function is optimized for life.

Introduction

Dentists need to be more involved in managing airway development and craniofacial formation in growing children. Already, dentists are increasingly involved in managing the care and airways of patients of all ages with sleep-related breathing disorders, which are common and often associated with vascular complications such as arterial hypertension, coronary heart disease and stroke.¹

Current available research is clear that airway obstruction impairs respiration. Impaired respiration can cause craniofacial malformation, malocclusion and jaw deformation. Research also shows that abnormal craniofacial formation can lead to airway obstruction, impaired respiration, impaired nasal breathing, chronic mouth breathing, sleep apnea, sleep disorders and lifelong ill-health.

Craniofacial form can follow craniofacial function and craniofacial function can follow craniofacial form. Therefore, both craniofacial form and function should be managed closely, particularly during the early ages of growth and development.

Early dental diagnosis and treatment of airway dysfunction and craniofacial malformation starting at birth is essential. Current literature shows that early orthodontic and orthopedic treatment impacts the airway and breathing. Orthodontic and orthopedic treatments that positively impact the airway and breathing can absolutely lead to a healthier and longer life.

The airway, mode of breathing, and malocclusion are so inter-related during growth and development that form can follow function and function can follow form. Since form can follow function and function can follow form both should be treated preventively, as early as possible.

It is certain that dysfunction of the human airway and breathing can cause malocclusion and skeletal deformation. Prolonged oral respiration (obligate mouth breathing) often results in dental and skeletal malformation in growing children. Some of these negative changes included excessive molar eruption, clockwise rotation of the mandible, increased anterior vertical face height, retrognathia and open bite. Often related and created low tongue posture can result in reduced lateral expansion and anterior development of the maxilla.²

Conversely, craniofacial malformation and/or malocclusion can negatively impact airway and breathing function. A simple subtle high narrow palate at birth can interfere with breast-feeding and even bottle-feeding such that aberrant tongue swallowing and mouth breathing habits begin.

Normal Airways and normal Breathing

Normal well-developed airways allow normal breathing through the nose with the mouth closed. Nasal breathing is important because it is now known to be vital to good health. Research has shown that air breathed through the nose is quite different to the body than air breathed through the mouth.

The benefits of nasal breathing begin within hours of birth when nasal nitric oxide gas can first be detected.³ Nitric oxide is a potent gas and a key component of human health.⁴ Nitric oxide is produced in the nasal sinuses, secreted into the nasal passages and inhaled through the nose. It is well known to prevent bacterial growth.⁵ In the lungs nitric oxide improves the ability to absorb oxygen.⁶ Nitric oxide is a strong vasodilator and brain transmitter. Furthermore, nitric oxide increases oxygen transport throughout the body and is vital to all body organs.

A good airway and normal nasal breathing is important because nasal airway obstruction has profound effects on the whole body and can even determine a patient's symptoms and complaints.⁷

Airway Obstruction

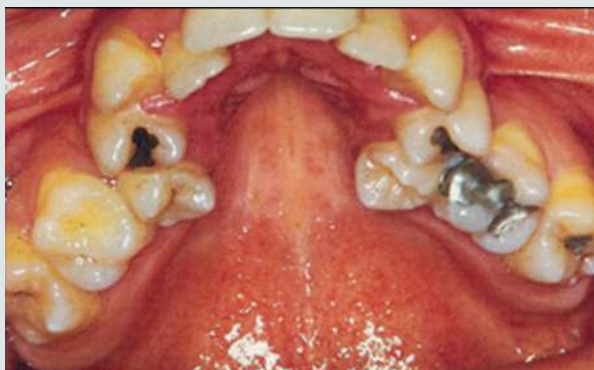Airway obstruction can cause breathing disorders, and craniofacial deformation and malocclusion. Upper airway obstruction can be subtle in children, but it can have long term consequences including failure to thrive, behavioral disturbances, developmental delay, sleep disorders and cor pulmonale.⁸

Airway obstruction can occur for a variety of reasons, including congenital abnormality, adenoid hypertrophy, tonsil hypertrophy, retruded maxilla [Fig. 1], retruded mandible [Fig. 2]. Obesity increases any present airway obstruction as the tongue, uvula and throat tissues enlarge.

Nasal obstruction, in particular, is a key villain and cause of abnormal growth and development of the face, jaws and dentition [Fig. 3]. Nasal obstruction has been linked to a variety of lifelong health disorders including hypertension, stroke, heart disease and even premature death.

Any airway obstruction can chronically affect life and even be life threatening. But nasal airway obstruction is a primary cause of chronic obligate mouth breathing, which can be so dangerous. Fortunately, certain dental treatments can increase nasal breathing and decrease mouth breathing.

Abb. 1

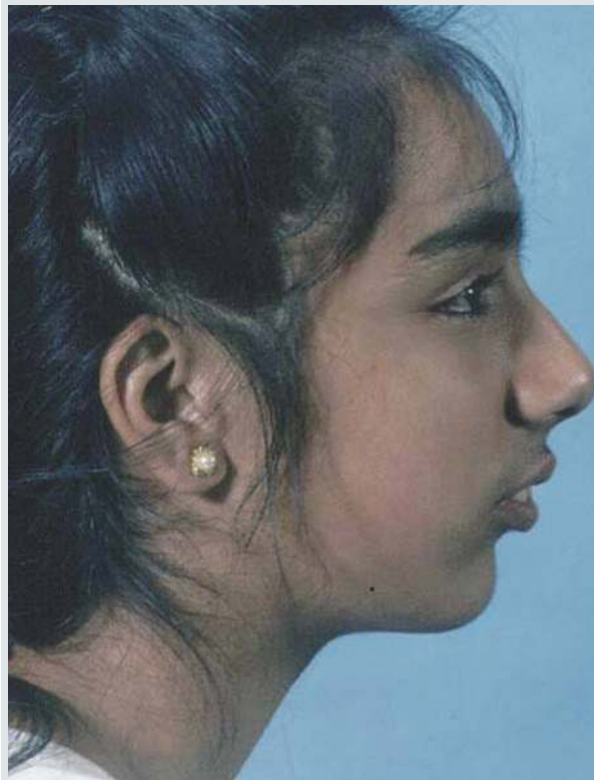


Small and/or High and/or Narrow and/or Retruded Maxilla (Palate)

Chronic mouth breathing

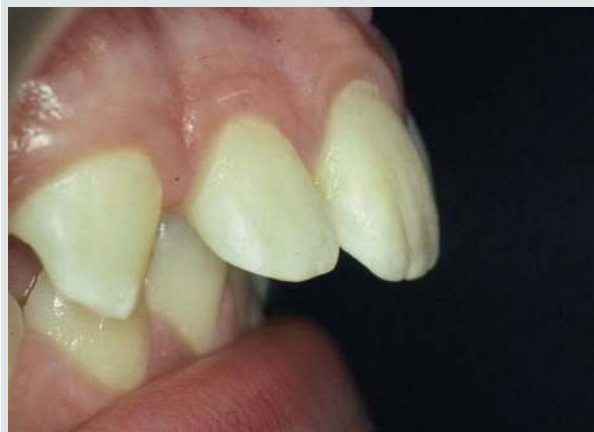Chronic obligate mouth breathing, from impaired nasal respiration, can cause progressively worse abnormal craniofacial development and malocclusion beginning at a very early age. Chronic mouth breathing interferes with proper maxillary and mandibular arch development by disrupting tongue, cheek and lip muscle forces

Abb. 2



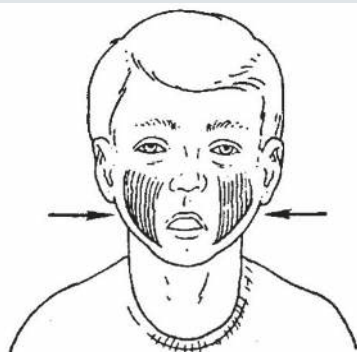
Small and/or Short and/or Narrow and/or Retruded Mandible (Lower Jaw)

Abb. 3

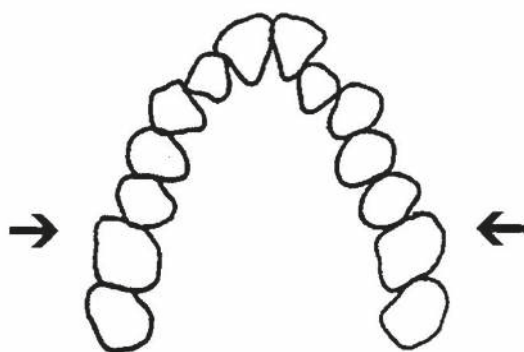


Class II Malocclusion with or without increased over-jet or "under-jet"

Abb. 4



Figure,2A



Constricted jaw due to constrictive muscle forces

Figure 2B

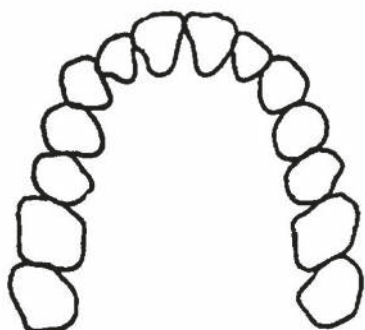
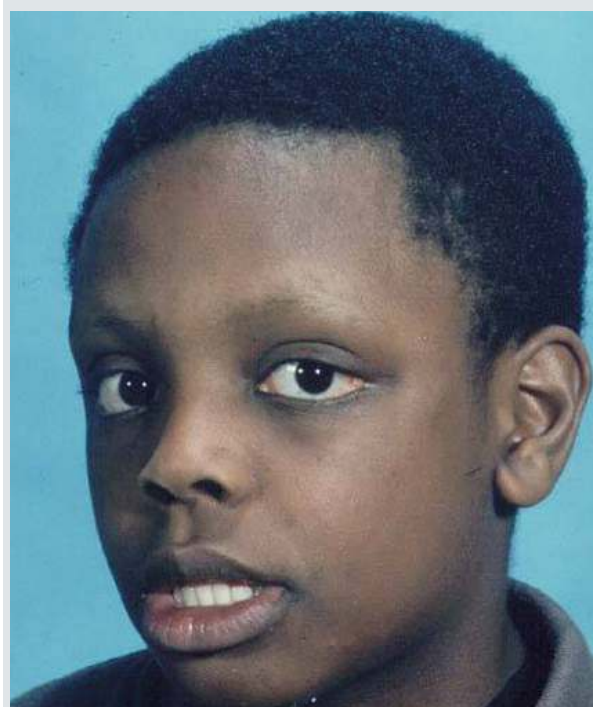

Diagram of negative action of the Buccinator when the tongue is in a lowered position.

[Figure #4]. Chronic oral breathing causes a down and backward positioning of the mandible, a vertical long-faced growth pattern and multiple abnormal growth patterns in the face, jaws and dentition that are very interrelated.

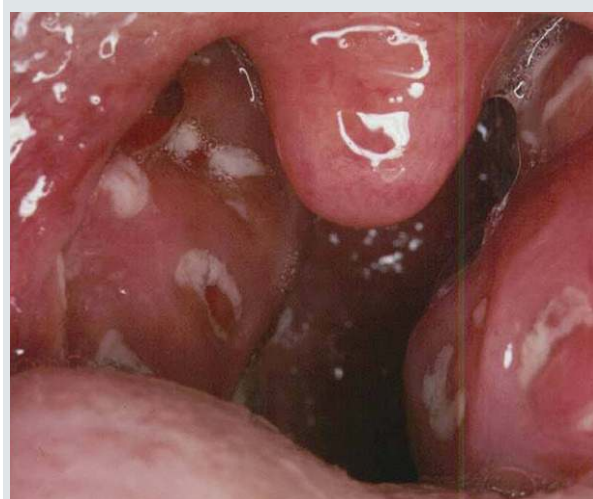Characteristics of chronic mouth breathing and respiratory obstruction syndrome include mouth breathing at rest [Figure #5], hypertrophied tonsils and/or adenoids [Figure #6], open-bite, cross-bite, excessive an-

Abb. 5



Mouth breather at Rest

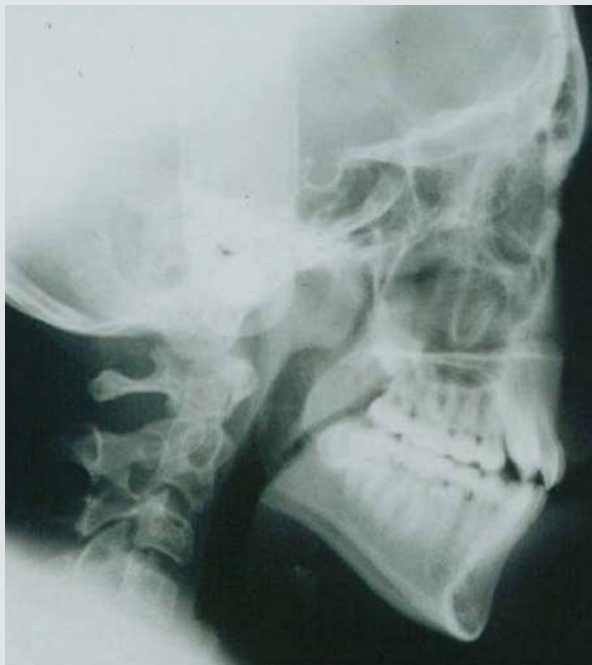Abb. 6a



Enlarged Adenoids & Tonsils

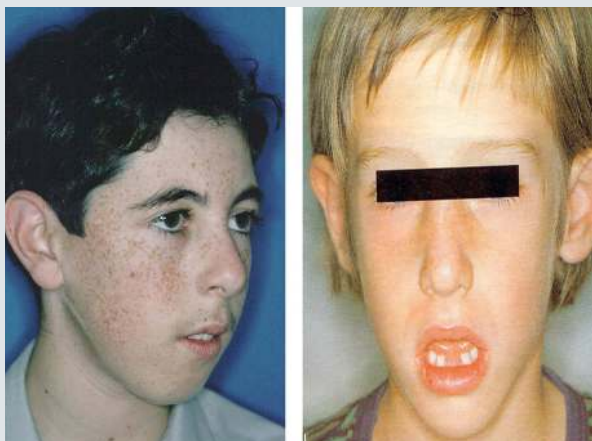terior faced height [Figure #7], incompetent lip posture, excessive appearance of the maxillary anterior teeth and gums [Figure #8], narrow external nares, allergic salute [Figure #9], "V" shaped palate [Figure #10] and venous pooling under the eyes [Figure #11]. Research shows there is a significant association between nasal resistance and increased over-jet, open bite, maxillary crowding, Angle Class II malocclusion and posterior cross-bite.⁹

Abb. 6b



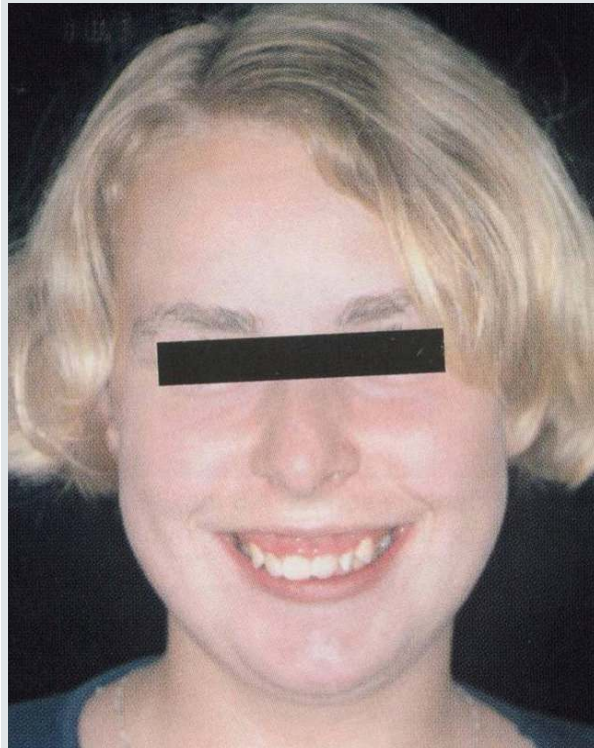Enlarged Adenoids & Tonsils

Abb. 7



Long Face

Abb. 8

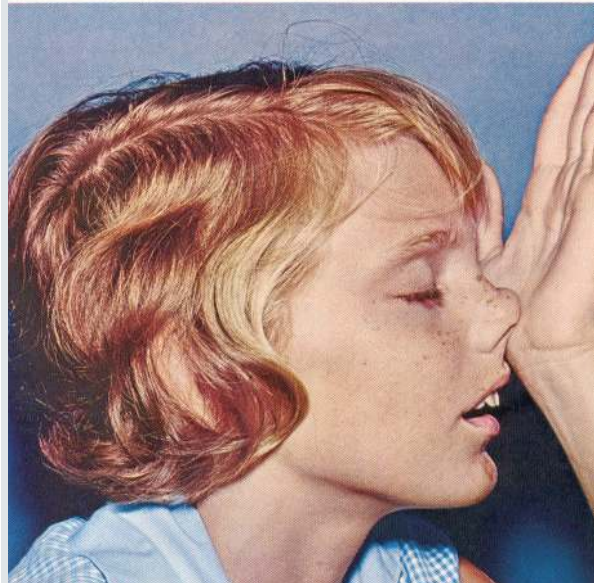

Gummy Smile

Abb. 9

Allergic facial mannerisms

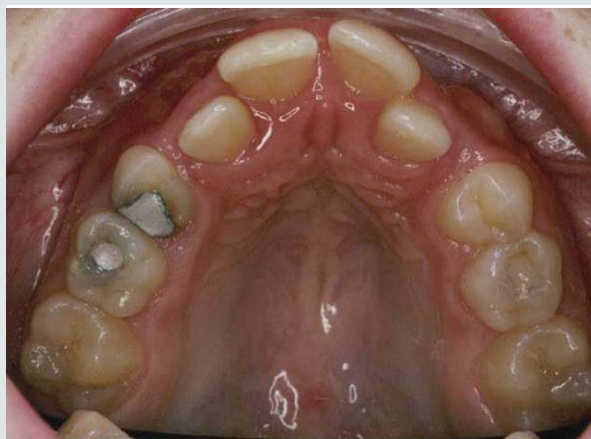fig. 1 Allergic salute. The patient pushes the nose forward and backward to relieve itching and the edematous vibrates from contact with the septum, thus allowing free passage of air. Child, aged 11 years, has had perennial allergic rhinitis since age 2.



Allergic Salute

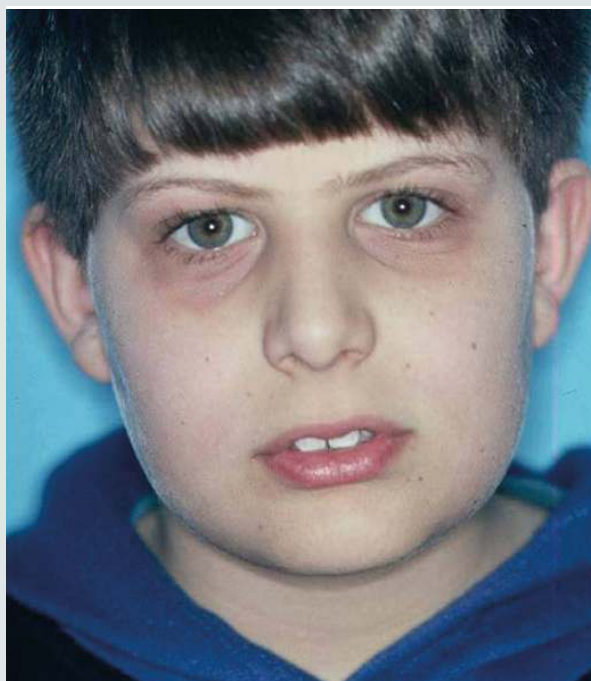Chronic mouth breathing, nasal incompetence, leads to disordered growth of the naso-ethmoid-maxillary unit and whole craniofacial complex. Chronic mouth breathing has been shown to be 4 times more common in children with orthodontic abnormalities.¹⁰ Oral respiration experiments in primates have shown that obstructed nasal airway leads to open mouth, lower mandible position and facial appearance and dental occlusion different from control animals.¹¹ Recognition and prevention of nasal incompetence in children and its treatment are important steps needed to ensure proper orthodontic stability and craniofacial growth.

Abb. 10



"V" Shaped Palate

Abb. 11



Venous Pooling

Craniofacial Growth

Craniofacial growth is eighty to ninety percent complete by age twelve, so most formation and/or deformation occurs by that age. Unfortunately, age twelve is still the average age that orthodontic and orthopedic treatment starts for most children worldwide. This must change.

The maxilla and mandible are nearly 50% grown at birth and about 90% grown by age 12. Therefore, about 80% of post-birth craniofacial growth occurs between birth and age 12. After age 12 only a fraction of post-birth craniofacial growth remains. It is plain to see that earlier treatment, from birth to age 12, when a majority of post birth growth potential occurs, can better impact craniofacial growth and development than after age 12.

In order to better influence craniofacial growth and development, disparities must be recognized and addressed much earlier than at the current age of twelve. More attention needs to be placed on routine craniofacial examination, diagnosis and treatment beginning at birth.

Early Diagnosis

Dentists are in a unique position to screen children for the recognizable signs and symptoms of mouth breathing, malocclusion, craniofacial anomalies and related conditions such as obstructive sleep apnea syndrome.¹² Early diagnosis of airway obstruction, obligate mouth breathing and malocclusion, with identification of the underlying causes, is essential to prevent worse orofacial growth abnormalities. It is now understood that early diagnosis can lead to earlier orthopedic treatment, which can be more effective, simpler and less restrictive than later age care.

Diagnosis of dental malocclusions and skeletal deformities associated with mouth breathing requires comprehensive and frequent orthodontic examinations.¹³ Routine early examination and diagnosis should begin at birth or soon after birth. All infants should be screened for craniofacial deformities that can affect airway form and function. Breast-feeding should be encouraged as it promotes good nasal breathing just as it decreases the incidence of obligate mouth breathing. The reverse

is true of bottle fed infants. So infants that are solely bottle-fed should be screened more often for the subtle effects of mouth breathing, aberrant tongue swallowing and thrusting, and palatal arch deformation.

At the age of two and three, subtle dental signs of nasal obstruction and mouth breathing can be seen. Some of the clearest signs include open bite, posterior cross-bite and excessive over-jet.

From ages three to twelve, early airway obstruction and craniofacial deformations too often magnify themselves to such an extent that time inversely relates to the ease and options for correction. To better recognize oral breathing caused dento-skeletal dysmorphism, cephalometric analysis should be used to evaluate facial architecture when obligate mouth breathing is suspected.

Early Treatment

Early treatment to reduce airway obstruction, obligate mouth breathing, craniofacial deformity and malocclusion is essential to normalizing growth and development. Early treatment maximizes the success of corrective orthodontics and orthopedics [Figure #12]. Dentists and otolaryngologists provide unique treatments that can reduce airway obstruction and craniofacial deformity.

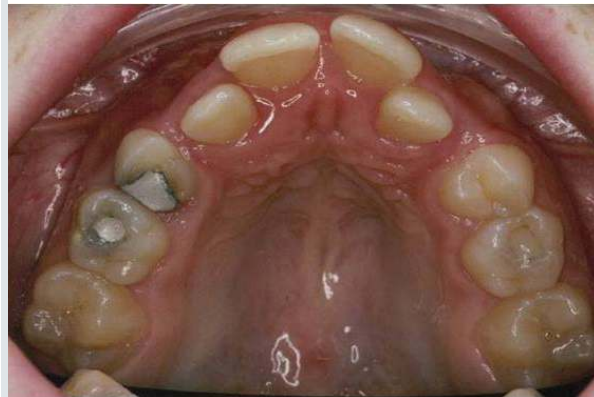Dental orthodontic appliances have been shown to improve the sagittal dimensions of the upper airway in children.¹⁴ Dental rapid maxillary expansion has been shown to be a simple, conservative method of treating impaired nasal respiration in patients 4 years to 30 years, but the younger the patient the better the long term results.¹⁵ Dental maxillary expansion is an effective method for increasing the width of narrow maxillary arches and it also reduces nasal resistance from levels seen with mouth breathing to levels consistent with normal nasal respiration.¹⁶

Otolaryngologists play a key role in early airway treatment. It has been shown that within a year following surgery (tonsillectomy and adenoidectomy) to improve breathing, obligate mouth breathers with dental malocclusion have improved dental occlusion.¹⁷

Dentists and Otolaryngologists (ENTs)

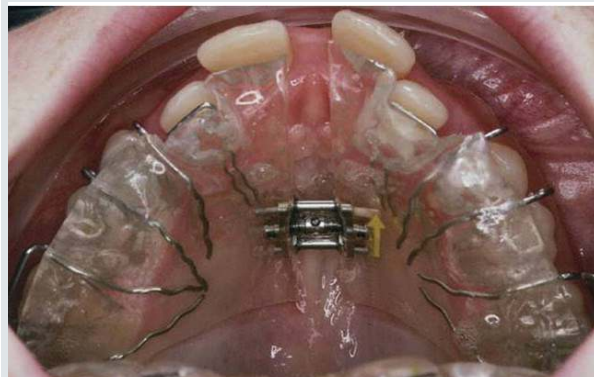Decades ago, otolaryngologists suggested they should work together with dentists to benefit patients (Crawford-1937, Fowler-1947). More recently, it was again suggested that better communication and interchange

Abb. 12a



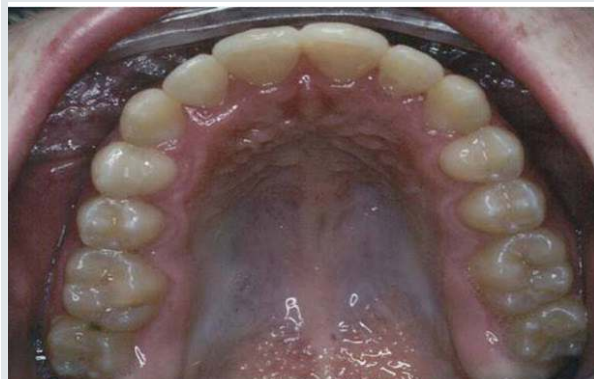Functional Appliances Can Develop Dental Arches, Jaws, Airways and Proper Swallow

Abb. 12b



Functional Appliances Can Develop Dental Arches, Jaws, Airways and Proper Swallow

Abb. 12c



Functional Appliances Can Develop Dental Arches, Jaws, Airways and Proper Swallow

of ideas between the various medical and dental practitioners caring for children with “Stuffy Noses, Long Faces and Dental Malocclusion” would benefit children.¹⁸ It is time for dental doctors and medical doctors to work together more in the areas of airway, breathing and orthodontics.

Literature

1. Mohsenin N, Mostofi MT, Mohsenin V. The role of oral appliances in treating obstructive sleep apnea. *J Am Dent Assoc.* 2003 Apr; 134(4):442-9.
2. Principato JJ. Upper airway obstruction and craniofacial morphology. *Otolaryngol Head Neck Surg.* 1991 Jun; 04(6): 881-90.
3. Schedin U, Norman M, Gustafsson LE, Herin P, Frostell D. Endogenous nitric oxide in the upper airways of health newborn infants. *Pediatr Res* 1996 Jul;40(1):148-51.
4. Page DC. *Your Jaws~Your Life*, SmilePage Publishing, 2003: p. 35
5. Lundberg JO, Farkas-Szallasi T, Weitzberg E, Rinder J, Lidholm J, Anggaard A, Hokfelt T, Lundberg JM, Alving K. High nitric oxide production in human paranasal sinuses. *Nat Med* 1995 Apr;1(4):370-3.
6. Issa A, Lappalainen U, Kleinman M, Bry K, Hallman M. Inhaled nitric oxide decreases hyperoxia-induced surfactant abnormality in preterm rabbits. *Pediatr Res* 1999 Feb;45(2):247-54.
7. Kimmelman CP. The systemic effects of nasal obstruction. *Otolaryngol Clin North Am* 1989 Apr; 22(2):461-6.
8. Defabjanis P. Impact of nasal airway obstruction on dentofacial development and sleep disturbances in children: preliminary notes. *J Clin Pediatr Dent.* 2003 Winter; 27(2):95-100.
9. Lopatiene K, Babarskas A. Malocclusion and upper airway obstruction. *Medicina (Kaunas).* 2002;38(3):277-83.
10. Ribault JY, Fourestier J, Gacon J, Renon P. Results of the evaluation of nasal respiration in maxillo-mandibular malocclusion in children. Apropos of 53 cases. *Rev Stomatol Chir Maxillofac.* 1990;91 Suppl 1: 96-8.
11. Harvold EP, Tomer BS, Vargervik K, Chierici G. Primate experiments on oral respiration. *Am J Orthod.* 1981 Apr; 79(4): 359-72.
12. Kawashima S, Peltomaki T, Laine J, Ronning O. Cephalometric evaluation of facial types in preschool children without sleep-related breathing disorder. *Int J pediatr otorhinolaryngol.* 2002 Apr 25; 63(2): 119-27
13. Limme M. Orthodontic studies in mouth breathing. *Acta Otorhinolaryngol Belg.* 1993; 47(2): 197-208.
14. Gao H, Xiao D, Zhao Z. Effects of Frankel II appliance on sagittal dimensions of upper airway in children. *Hua Xi Kou Qiang Yi Xue Za Zhi.* 2003 Apr 20; 2 116-7.
15. Gray LP. Results of 310 cases of rapid maxillary expansion selected for medical reasons. *J Laryngol Otol.* 1975 Jun; 89(6): 601-14.
16. Hershey HG, Stewart BL, Warren DW. Changes in nasal airway resistance associated with rapid maxillary expansion. *Am J Orthod.* 1976 Mar; 69(3): 274-84.
17. Weider DJ, Baker GL, Salvatoriello FW. Dental malocclusion and upper airway obstruction, an otolaryngologist's perspective. *Int J Pediatr Otorhinolaryngol.* 2003 Apr; 67 (4): 323-31.
18. Cole P. Doctors and dentists: review of a symposium. *J Otolaryngol.* 1989 Jun; 18



Abb. Autor: Dr. Derek Mahony, Sydney, is a world renowned Specialist Orthodontist who has spoken to thousands of practitioners about the benefits of interceptive orthodontic treatment. Early in his career he learned from leading clinicians the dramatic effect functional appliance therapy can afford patients in orthodontic treatment. He has been combining the fixed and functional appliance approach ever since. His lectures are based on the positive impact such a combined treatment approach has had on his orthodontic results and the benefits this philosophy provides from a practice management viewpoint. After completing his Dental Degree at the University of Sydney. Dr Mahony proceeded to the United Kingdom where he completed his Masters Degree in Orthodontics at the Eastman Dental Hospital, Institute of Dental Surgery, London. Further studies led to the successful completion of a Diploma in Orthodontics at the Royal College of Surgeons, Edinburgh. He has also passed the Royal College of Dentists in Canada post graduate examination in the field of orthodontics. Dr Mahony has passed examinations leading to a postgraduate qualification in Dentofacial Orthopaedics from the Royal College of Physicians and Surgeons in Glasgow. He has also attained his Membership in Orthodontics qualification from the Royal College of Surgeons, England. Dr Mahony is considered by some to be the “next leading lecturer on functional/fixed orthodontics.” He is a contributing editor to the *Journal of Clinical Paediatric Dentistry*, *International Orthodontic Journal* and *Spanish Journal of Dentofacial Orthopaedics*. (see Professional Activity section)